

Arthroscopic Distal Scaphoid Resection for Scapho-Trapezium-Trapezoid Arthritis

Riccardo Luchetti¹ , Andrea Atzei²,
and Roberto Cozzolino¹

HAND
1–8
© The Author(s) 2019
Article reuse guidelines:
sagepub.com/journals-permissions
DOI: 10.1177/1558944719864451
hand.sagepub.com

Abstract

Background: The purpose of this study was to describe the technique of arthroscopic resection of the scaphoid head and evaluate both the clinical and radiographic results of scapho-trapezium-trapezoid osteoarthritis cases. **Methods:** Seventeen cases (13 men and 4 women) with a mean age of 57 years (24–74 years) were operated on from 2002 to 2015. Inclusion criteria were nontraumatic radial-sided wrist pain without improvement after 4 months of conservative treatment and positive radiographic images demonstrating the presence of osteoarthritis. All cases were evaluated preoperatively and postoperatively using visual analog scale, wrist range of motion (ROM), grip strength, and patient's work status (Mayo Wrist Score). Disabilities of the Arm, Shoulder, and Hand (DASH) and Patient-Rated Wrist/Hand Evaluation (PRWHE) questionnaires were also administered. The technique consisted of performing a 3- to 4-mm round-shaped scaphoid head resection via arthroscopy while preserving the scaphotrapezial and scaphocapitate ligament insertions. **Results:** At an average follow-up of 24 months, all the patients were satisfied. The results showed statistically significant improvement in pain at rest ($P = .001$), under maximal load ($P = .0001$), and in Mayo Wrist Score (MWS) ($P = .0001$). Wrist ROM, grip strength, DASH, and PRWHE showed an improvement without reaching statistical significance. The mean preoperative radiolunate (RL) X-ray measurement angle was 17° (-10° to 35°). The postoperative mean value was 25° (0° – 45°). In the preoperative radiographic evaluation, 11 cases exceeded the “critical” 15° RL angle. At follow-up, the RL angle increased in 10 cases and remained unchanged in 7 cases. None of these cases became symptomatic. Transitory neurapraxia of the dorsal superficial branch of the radial nerve was observed in 1 case. Damage of the dorsal branch of the radial artery was immediately fixed. **Conclusions:** Arthroscopic resection of the distal portion of the scaphoid due to scapho-trapezium-trapezoid osteoarthritis demonstrated an effective and safe technique with less complications than open surgery.

Keywords: STT arthroscopy, STT arthritis, STT resection, STT arthroscopic resection, wrist arthroscopy

Introduction

Arthroscopic surgery for scapho-trapezium-trapezoid joint osteoarthritis (STT OA) has been proposed by several authors with good results.^{1–15} The arthroscopic techniques include debridement and/or resection with or without interposition. Resection is indicated for advanced chondropathy or clear STT arthritis. A suggested procedure for open resection for biomechanical purposes to prevent the occurrence of the so-called carpal instability nondissociative-dorsal intercalated segment instability (CIND-DISI) is pyrocarbon prosthesis interposition.^{16–20} However, when prosthesis interposition was used in association with arthroscopic resection, it is proved that it did not add any advantage to the final results in comparison with a simple distal head scaphoid resection.¹¹ Therefore, simple conservative resection of the scaphoid distal pole is suggested.

The aim of this study was to describe the technique of arthroscopic resection of the scaphoid head and to evaluate the clinical and radiographic results of a series of cases affected by STT OA.

Materials and Methods

From 2000 to 2016, 32 patients with STT OA have been operated on for scaphoid head resection via arthroscopy. The main surgical inclusion criteria were STT OA without history of previous trauma and persistence of symptoms

¹Rimini Hand Surgery and Rehabilitation Center, Italy

²Fenice Hand Surgery and Rehabilitation Team, Treviso, Italy

Corresponding Author:

Riccardo Luchetti, Rimini Hand Surgery and Rehabilitation Center,
Via Pietro da Rimini 4, Rimini 47924, Italy.
Email: riccardoluchetti53@gmail.com

even after 4 months of conservative treatment. The presence of a concomitant osteoarthritis of the first carpometacarpal joint does not exclude an arthroscopic treatment of the STT joint but favors the simultaneous treatment of the 2 pathologies in the same way or through a classic open surgical treatment with trapeziectomy and suspensoplasty. A further inclusion criterion is the presence of a radiolunate (RL) angle of less than 35° according to Garcia-Elias and Lluch.¹⁸ However, Pegoli et al¹¹ have already shown that patients with RL angle $\geq 35^\circ$ had no clinical problems after arthroscopic resection despite the increase in RL angle. The exclusion criteria were the presence of midcarpal arthritis or a diffuse wrist arthrosis.

The cases were evaluated preoperatively and at follow-up. Pain level thresholds at rest, as well as pain under maximal load, were evaluated using the visual analogue scale (VAS) from 0 to 10 points. A standard manual goniometer was used to measure wrist range of motion (ROM), including wrist flexion-extension and radioulnar deviation. Mean grip strength was evaluated using a handheld dynamometer (Jamar; Preston Corp, Jackson, MS) in grip positions 1 to 5, both in kilograms and in percentage compared with the contralateral unaffected side. Patient's work status was also taken into consideration. The MWS (0-100 points)²¹ was then calculated to obtain an objective wrist function assessment measurement in all patients. The best values were considered to be those which almost reached the Mayo Wrist Score (MWS) of 100 points. Subjective hand function was assessed using the Italian validated versions of both the Disabilities of the Arm, Shoulder, and Hand (DASH) questionnaire²² and Patient-Rated Wrist/Hand Evaluation (PRWHE) score,²³ both preoperatively and postoperatively.

Preoperative and postoperative radiographs (lateral and posteroanterior views) were taken in all cases. The RL angle was measured in both the pre- and postoperative radiographs to compare the results. To confirm the clinical diagnosis, preoperative magnetic resonance imaging was taken in uncertain cases with negative radiographs.

Surgical Technique

The patient's hand/wrist position for performing an STT arthroscopy is identical to that of all other wrist arthroscopy postures.^{10,14,24,25} The finger traps are applied to the second and third finger. Traction to the thumb might help in gaining better articular distraction of the STT for the palmar approach, but it was not used consistently. A countertraction of 3 kg, applied to the arm immediately above the elbow, is sufficient to obtain good joint distraction. Dry arthroscopy is always used.^{26,27} The joint is flushed by introducing liquid via syringe attached to the arthroscope²⁷ (Figure 1). This step is necessary to remove the debris and wash the instruments, as well as the joint. A 1.9-mm wide-angle videoarthroscope is always used. The midcarpal ulnar portal is

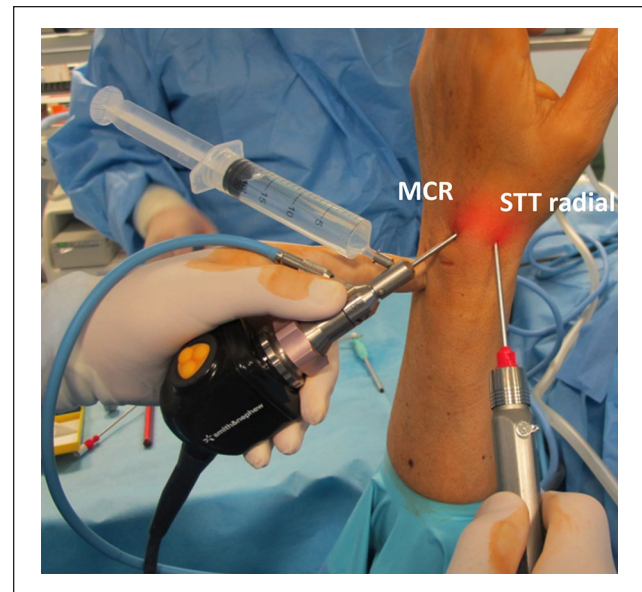


Figure 1. Arthroscopic technique for STT joint.

Note. Scope in MCR and burr in radial STT portal. Joint flushing is done by introducing liquid via syringe connected with the arthroscope. Liquid is introduced into the joint by shaver aspiration. Once the liquid is introduced, the syringe is removed from the arthroscope. STT = scapho-trapezium-trapezoid; MCR = midcarpal radial.

always the first and easiest portal to enter to evaluate the metacarpal (MC) joint.^{3,5} The midcarpal radial (MCR) portal is prepared under arthroscopic control using an out-in technique. As the scope is introduced into the MCR portal, the radial side of the MC joint is evaluated. This portal permits the surgeon to reach the scapholunate (SL) joint and to test its stability according to Geissler and Haley's²⁸ and Messina et al's²⁹ evaluation maneuvers and also to completely assess the MC joint. The scope is moved radially and distally along the scaphocapitate (SC) joint space: as the corner between the capitate, trapezoid, and scaphoid is reached, the scope is turned 90° or 180° to obtain a better view of the STT joint. Subsequently, the STT dorsal portal is made with the scope in the same position, using an out-in technique. Therefore, the evaluation of the STT joint starts with the scope in the MCR or STT dorsal portal. The STT dorsal portal is localized between the extensor pollicis brevis and extensor pollicis longus (EPL) tendons or between the EPL and the extensor carpi radialis longus tendons. The dorsal portal is a working portal at the beginning, but the scope might be switched from the MCR to the STT dorsal portal^{1,2,9,10,12-14} to allow a complete evaluation of the STT joint. My favorite working portal is the STT radial portal⁵ localized between the abductor pollicis longus and EPL, always made in an out-in technique. The palmar portal can be made using the Baré et al⁴ and Tham and Dagge¹⁵ method. It is localized between the flexor carpi radialis (FCR) tendon and the STT ligaments. The palmar portal can

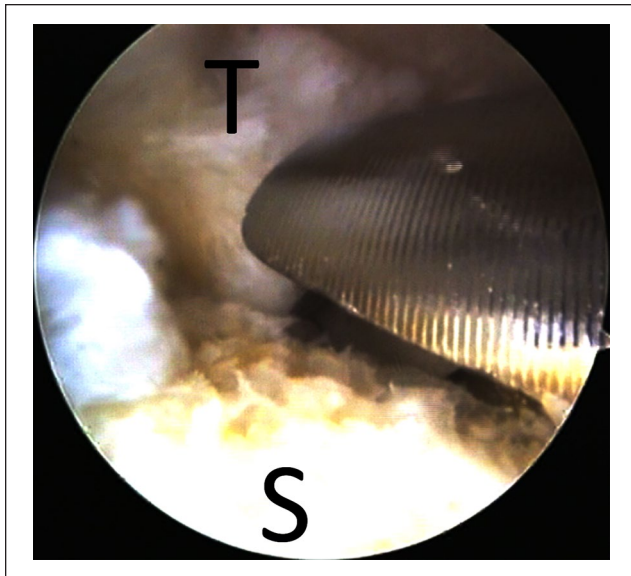


Figure 2. Scaphoid head resection with a burr.
Note. S = scaphoid; T = trapezium.

also be established using an in-out technique through the STT dorsal portal. Therefore, the progression of the production of STT portals is: MCR first followed by the STT dorsal and the STT radial portal. STT palmar portal is the last and is produced as is needed. Synovitis and various degrees of scaphoid head, trapezium, and trapezoid chondropathy might be found. A 2.9-mm shaver introduced into the STT radial portal will help perform a synovectomy, where the synovial tissue is often localized close to the border of the joint. Portals should be switched to allow a complete synovectomy and debridement when needed.^{1,2} Particular attention should be paid to not damage the ligaments when performing synovectomy close to the scaphoid's capsular insertion. Clear articular joint degeneration will be removed by resection of the scaphoid's distal portion. The dorsal and radial portals are considered the traditional STT working portals. The arthroscopic resection proceeds progressively from the radial-dorsal to the palmar-ulnar side. The "burr" (2.9 mm or 3.5 mm) is the typical instrument used (Figure 2), and the STT portals should be widened to permit its easy entry into the wrist. Correct resection of the scaphoid head is demanding because the remaining portion should obtain a round shape (Figure 3). The use of the round burr produces grooves that eventually need to be smoothed out. The rules of switching the portals are always valid to achieve a complete and smoothed resection. Bone resection should not exceed the articular margin of more than 3 to 4 mm, and particular attention should be paid in preserving the capsular ligaments to prevent the onset of STT joint instability (Figures 3 and 4). The most anterior portion of the scaphoid head is the part less visible and not easily

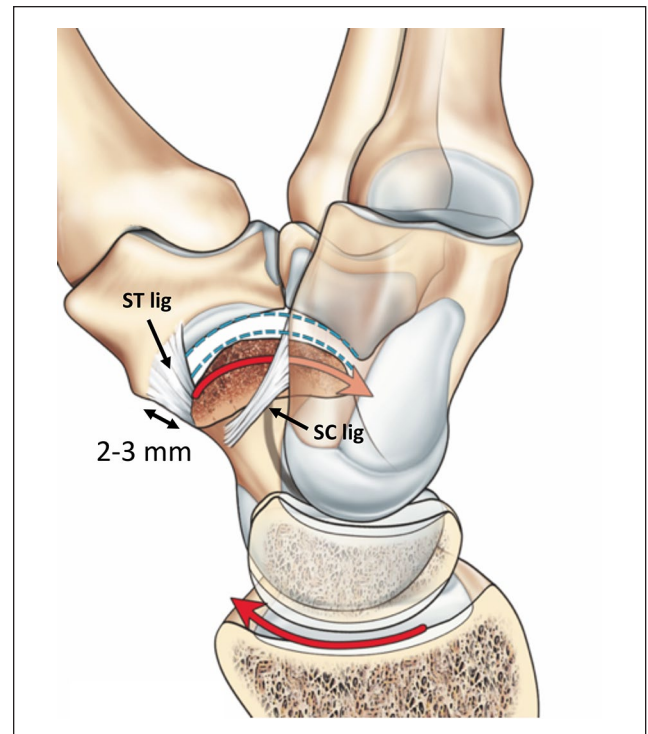


Figure 3. The amount of bone resection of the scaphoid head. Red arrows denote the possible motion of the first carpal row after resection.
Note. ST lig = scaphotrapezial ligament; SC lig = scaphocapitate ligament.

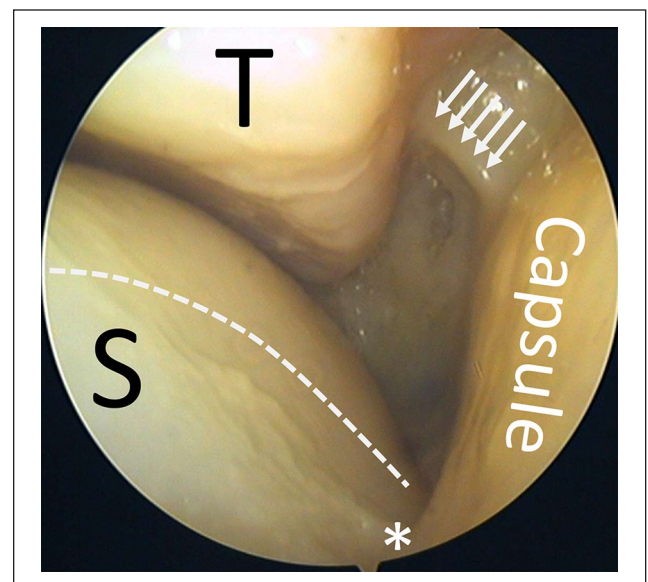


Figure 4. Arthroscopic image that shows the dorsal-radial capsular attachment (white arrows and asterisk) to the T and S. The white dotted line shows the level of scaphoid head resection.
Note. S = scaphoid; T = trapezium.

accessible by the instruments that are positioned in the dorsal portal. On the contrary, the radial portal should help in permitting the entire anterior portion resection. Insufficient resection of the anterior portion of the scaphoid head produces a painful palmar STT conflict, which appears on radiographs and becomes symptomatic during wrist motion. Changing from the second and third finger to thumb traction will increase the joint space, thus permitting better exposure of the distal scaphoid's volar border. In this position, the border will be removed, maintaining the burr in the radial portal. In our experience, the palmar portal is rarely used.

Complications

The arthroscopic resection of the scaphoid's distal portion is performed in a very narrow joint space, less than 1 cm, and the instrument can easily come out of the portal and joint space. The STT radial and dorsal portals are very close to both the dorsal branch of the radial artery (DBRA) and one of the dorsal sensory branches of the radial nerve (DSBRN); therefore, there is a predisposition of possible iatrogenic damage to these structures. Establishing the dorsal portal directly with the out-in technique may require several attempts and cause risk of damage of neurovascular structures.¹⁵ The unintentional exit of an instrument, such as the shaver or the burr, from the dorsal portal is also a source of risk in relation to these structures, as well as the attempt to enter again with the same tools in the same portal. The volar portal is close to the FCR and scaphotrapezial (ST) ligaments which could be damaged with the burr or shaver under the work condition. Widening the portals should be a maneuver that facilitates these procedures and preserves the underlying structures from iatrogenic damage. Incomplete bone resection of the scaphoid head's palmar portion can cause a painful bone on bone conflict that sometimes needs a secondary surgical revision.

Postoperative Rehabilitation

The wrist is immobilized in a splint for 4 weeks. Daily dressings are associated with active/gentle wrist mobilization. Rehabilitation starts after 20 days to 1 month and consists of progressive mobilization of both the wrist and thumb with progressive resisted digital pinch and grip exercises. It normally takes about 3 months for complete progressive healing to occur.

Statistical Analysis

Preoperative and postoperative data for pain, wrist ROM, grip strength, MWS, DASH, and PRWHE questionnaires were compared statistically in all cases using the 2-tailed

matched-pair Student *t* test. Differences were considered significant when the *P* value was .05.

Results

Seventeen cases (13 men and 4 women) were operated on from 2002 to 2015 and were included in this study since complete data collection was obtained. The mean age was 57 years (24-74 years), and the right hand was affected in 10 cases. At an average follow-up of 24 months (8-113 months), all the patients were satisfied. The results (Table 1) showed statistically significant improvement in pain at rest ($P = .001$), under maximal load ($P = 0.0001$) and in MWS ($P = .0001$). Wrist ROM and grip strength were unchanged. The DASH and PRWHE showed an improvement without reaching statistical significance, probably due to the fact that not all cases received the questionnaires.

The preoperative mean RL X-ray measurement angle was 17° (-10° to 35°), whereas the postoperative mean value was 25° (0° - 45°). In the preoperative radiographic evaluation, 11 cases exceeded the "critical" 15° RL angle.²¹ At follow-up, the RL angle increased in 10 cases, whereas it was unchanged in 7 cases. None of these cases became symptomatic. No case was operated on due to consequences of a minimal increase in the RL angle.

Neurovascular complications were observed in 2 cases: in the first case, the DBRA was damaged using the dorsal STT portal and it was immediately fixed. In the second case, a transitory DSBRN paresthesia occurred when using the radial STT portal. This case spontaneously healed within 3 months.

Discussion

Arthroscopy of the STT OA has evolved in recent years, producing alternative solutions to open surgery.^{4,11,15} It has grown from being used for a simple diagnostic inspection to performing a synovectomy, debridement,^{1,2} and, up until now, a resection of the scaphoid's distal portion.^{10,11,14,15} During the surgery, particular attention should be paid to the amount and shape of the scaphoid's distal portion that is being resected. A small resection corresponding to no more than 3 to 5 mm is sufficient, and its shape should be rounded especially in its volar portion to prevent secondary bone conflict during wrist motion. The amount of resection is usually calculated by the instrument's dimensions and in the way that an easy passage of the 2.9- to 3.5-mm burr is allowed into the STT joint (Figure 2). To maintain STT joint complex stability, the amount of bone resection should not exceed the border of the scaphoid head's capsuloligamentous insertion (Figure 4). Therefore, the capsular attachment must be preserved. For this reason, the technique is quite demanding and requires a long learning curve. If the capsuloligament is largely detached from the scaphoid

Table 1. Preoperative and Postoperative Results With Statistical Analysis.

	Preoperative				Postoperative				t	df	P
	Mean	95% CI	SD	No.	Mean	95% CI	SD	No.			
Pain (at rest)	2.88	1.63 to 4.14	2.64	17	0.47	-0.04 to 7.69	1.07	17	4.29	16	.001*
Pain (stress)	7.65	6.73 to 8.57	1.93	17	3.00	1.66 to 7.03	2.83	17	6.14	16	.0001**
Flexion, (degree)	60.53	55.27 to 65.79	11.06	17	61.41	56.27 to 65.11	10.82	17	-.27	16	ns
Extension, (degree)	62.59	56.45 to 68.73	12.92	17	62.18	58.73 to 68.66	7.26	17	.11	16	ns
Flexion to extension, (degree)	123.12	112.78 to 133.45	21.74	17	123.59	116.37 to 128.18	15.19	17	-.07	16	ns
Radial deviation, (degree)	21.94	17.65 to 26.23	9.02	17	18.29	14.26 to 21.91	8.48	17	1.52	16	ns
Ulnar deviation, (degree)	31.24	26.58 to 35.89	9.79	17	35.41	31.71 to 42.37	7.78	17	-1.34	16	ns
Radial-ulnar deviation, (degree)	53.18	45.48 to 60.87	16.20	17	53.71	47.22 to 57.11	13.64	17	-.11	16	ns
Grip strength, (kgf)	18.47	14.11 to 22.83	9.17	17	18.82	15.11 to 23.55	7.82	17	-.31	16	ns
MWS	65.59	58.92 to 72.25	14.02	17	83.82	78.41 to 83.82	11.39	17	-5.09	16	.0001**
DASH	34.36	28.83 to 45.91	15.42	12	27.62	13.29 to 27.00	27.09	12	.89	11	ns
PRWHE	55.36	45.87 to 68.71	19.98	11	37.95	16.85 to 34.46	34.75	11	1.66	10	ns

Note. CI = confidence interval; MWS = Mayo Wrist Score; DASH = Disabilities of the Arm, Shoulder, and Hand; PRWHE = Patient-Rated Wrist/Hand Evaluation; ns = not significant.

*statistically significant.

**highly statistically significant.

during bone resection (especially on the palmar side, as it often happens in open surgery), instability of the first proximal carpal row might occur, producing a clear CIND-DISI, and patients eventually may become symptomatic.^{18,19} In the present series, none of the patients became symptomatic and needed secondary surgery. Therefore, the quality of these studies depends on the particular attention paid when performing the bone resection and ligament preservation. The radial STT portal proposed by Carro et al⁵ is the most effective work portal in association with the dorsal one. It allows the surgeon to obtain complete control and resection of the scaphoid's distal head in a rounded fashion. In our experience, the palmar STT portal proposed by Baré et al⁴ and Tham and Dagge¹⁵ was rarely used, and when used, it was easily performed using an "in-out" technique from the dorsal portal.

Arthroscopic resection of the scaphoid's distal portion for STT OA provides good functional results. The wrist ROM and grip strength did not change, whereas pain and global wrist function (MWS) significantly improved (Table 1). Rarely does pain completely disappear, but often the results of this surgery decrease the pain sufficiently enough to render acceptable clinical and functional results. Some patients did not report complete satisfaction from arthroscopic surgery, but their functional results were definitely better than preoperatively. The mean return to work times are long and on average around 60 to 90 days. It was always in relation to the type of manual tasks that the patient performed. A longer recovery period was needed for patients who performed heavy work.

Open surgery for STT resection provides similar results for pain, wrist ROM, and grip strength,³⁰ but the incidence of complications¹⁷ is higher than in this arthroscopy technique (eg, the occurrence of complex regional pain syndrome and secondary carpal instability [CIND]). From a technical point of view, scaphoid resection renders almost the same results, but open surgical exposure might determine some ligament tears with eventual biomechanical changes in the first carpal row (CIND).

Arthroscopic distal scaphoid resection was proposed by several authors.¹⁻¹⁵ Their results, even at different follow-up times, were strongly similar, demonstrating that the technique was effective. Fontes³¹ performed an arthroscopic 3 mm distal scaphoid resection in 8 patients (7 STT OA and 1 case of STT arthrodesis nonunion) with excellent results and without complications at 1 year of follow-up. Wrist motion (radial inclination) and grip strength increased and pain disappeared.

Ashwood et al¹ suggested debridement of synovitis, chondral flaps, and rim osteophytes of the STT with minimal or no bone resection in 10 cases with positive results. Nine out of 10 patients reached good or excellent subjective results, with pain reduction from 9 to 1, and the mean Green and O'Brien wrist score improved from 63 to 91.

Tham and Dagge¹⁵ performed an arthroscopic distal scaphoid resection associated with tendon interposition for isolated STT OA in 7 patients. At a mean follow-up of 13.3 months, 5 patients had no pain or mild pain during intermittent activity. No changes were demonstrated for wrist ROM, and grip strength improved from 4 to 7.6 kg. Two failures were due to inadequate resection of the distal scaphoid.

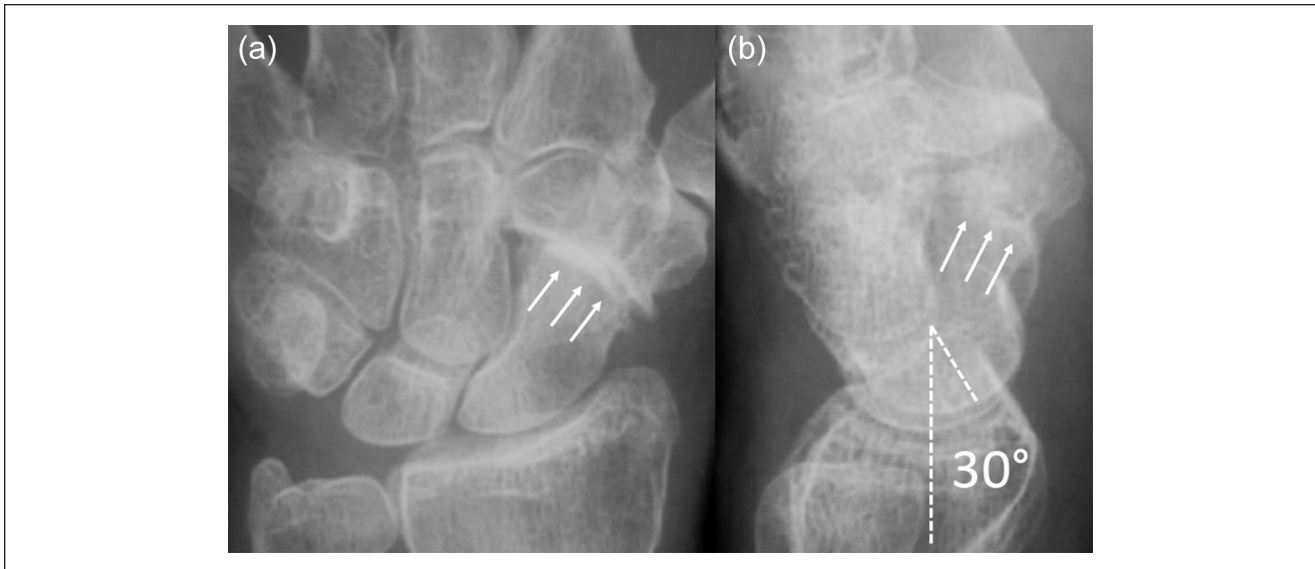


Figure 5. Preoperative radiographic images of scapho-trapezium-trapezoid (STT) arthritis: (a) posteroanterior and (b) lateral views of wrist with STT arthritis (white arrows); preoperative dorsal intercalated segment instability was calculated in the lateral view.

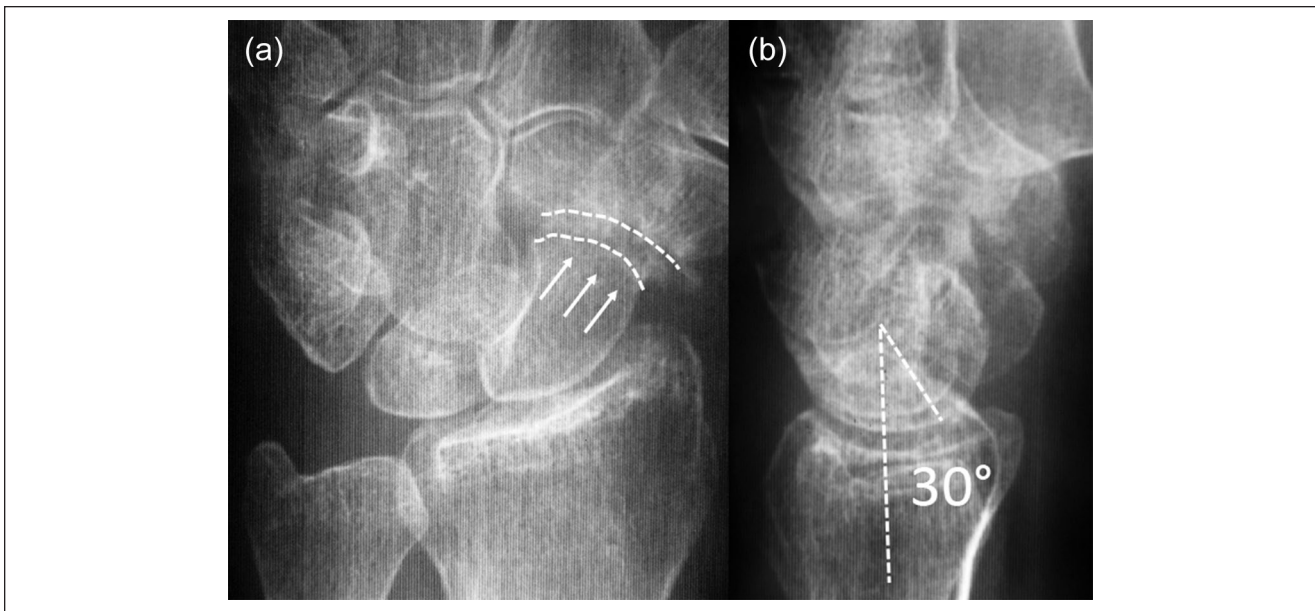


Figure 6. Postoperative radiographic images (a, b) of the same patient. Note the amount of the scaphoid bone resection (white arrows and double dotted lines) and the persistence of the same dorsal intercalated segment instability.

Cobb,⁶ after STT arthroscopic resection, demonstrated a progressive recovery of grip strength and wrist motion associated with significant improvement of pain at 4, 12, 26, and 52 weeks. At 1 year of follow-up, the average DASH score was 14; pain, 1; and grip strength, 52 kgf.

Mathoulin and Darin¹⁰ described 2 separate groups of patients with STT OA operated by arthroscopic distal scaphoid resection with and without pyrocarbon interposition. The 2 groups were not compared but both demon-

strated good results. However, the group with pyrocarbon interposition had 2 implant dislocations.

Pegoli et al¹¹ compared 2 groups of patients, with and without pyrocarbon prosthesis interposition after distal scaphoid resection for STT OA. No statistical differences were found between the 2 groups for wrist ROM, grip strength, and pain improvement, establishing that prosthesis interposition is not significant when the resection is minimal and the technique is performed by arthroscopy.

Radiographic images of arthroscopic STT resection never showed a clear separation of the scaphoid from the trapezium and trapezoid, as in open surgery, due to the fact that resection is always limited at 2 to 4 mm (Figures 5 and 6). Fluoroscopy performed during the arthroscopy, with joint distraction, shows the best images of the STT resection. After arthroscopic distal scaphoid resection, the DISI deformity increased in 59%, but it never reached significant values,¹¹ and patients had no symptoms related to this. Seldom does the RL angle remain unchanged. No reoperations are described in the literature for moderate CIND-DISI secondary to arthroscopic resection of the STT joint.

Conclusion

Arthroscopic resection of the distal pole of the scaphoid seems to provide optimal functional results at mid-term follow-up. The procedure is technically demanding due to the fact that the resection should be done in a rounded fashion preserving the scaphoid attachment of the SC and ST ligaments. It is certainly an advanced arthroscopic procedure that requires considerable experience in arthroscopic technique and therefore performed only by skillful and expert arthroscopy surgeons. Complications are rare and mainly involve the neurovascular structures.

Ethical Approval

This study was approved by our institutional review board.

Statement of Human and Animal Rights

All procedures followed were in accordance with the ethical standards of the responsible committee on human experimentation (institutional and national) and with the Helsinki Declaration of 1975, as revised in 2008.

Statement of Informed Consent

Informed consent was obtained from all individual participants included in the study.

Declaration of Conflicting Interests

The author(s) declared no potential conflicts of interest with respect to the research, authorship, and/or publication of this article.

Funding

The author(s) received no financial support for the research, authorship, and/or publication of this article.

ORCID iD

Riccardo Luchetti  <https://orcid.org/0000-0003-2918-9583>

References

- Ashwood N, Bain G, Fogg Q. Results of arthroscopic debridement for isolated scaphotrapeziotrapezoid arthritis. *J Hand Surg Am.* 2003;28:729-732.
- Ashwood N, Bain GI. Arthroscopic debridement for isolated scaphotrapeziotrapezoid arthritis. In: Slutsky DJ, Nagle D, eds. *Techniques in Wrist and Hand Arthroscopy*. Philadelphia: Churchill Livingstone; 2007:234-238.
- Badia A. Small joint arthroscopy. In: Geissler WB, ed. *Wrist and Elbow Arthroscopy: A Practical Surgical Guide to Techniques*. 2nd ed..New York: Springer Verlag; 2015:321-340.
- Baré J, Graham AJ, Tham SK. Scaphotrapezial joint arthroscopy: a palmar portal. *J Hand Surg Am.* 2003;28:605-609.
- Carro L, Golano P, Farinas O, et al. The radial portal for scaphotrapeziotrapezoid arthroscopy. *Arthroscopy.* 2003;19:547-553.
- Cobb TK. Arthroscopic STT arthroplasty. *J Hand Surg.* 2009;34:42-43.
- Cobb TK, Sterbank P, Lemke J. Arthroscopic resection arthroplasty for treatment of combined carpometacarpal and scaphotrapeziotrapezoid (pantrapezial) arthritis. *J Hand Surg.* 2011;36A:413-419.
- Cobb TK. Partial trapeziectomy and soft tissue interposition. In: Geissler WB, ed. *Wrist and Elbow Arthroscopy: A Practical Surgical Guide to Techniques*. New York: Springer Verlag; 2015:303-312.
- Da Rin F, Mathoulin C. Traitement arthroscopique de l'arthrose scapotraperotrapezoidienne. *Chir Main.* 2006;25: S254-S258.
- Mathoulin C, Darin F. Arthroscopic treatment of scaphotrapeziotrapezoid osteoarthritis. *Hand Clin.* 2011;27:319-322.
- Pegoli L, Pozzi A, Pivato G, et al. Arthroscopic resection of distal pole of the scaphoid for scaphotrapeziotrapezoid joint arthritis: comparison between simple resection and implant interposition. *J Wrist Surg.* 2016;5:227-232.
- Slutsky DJ. Arthroscopic treatment of scaphotrapeziotrapezoidal osteoarthritis. In: Slutsky DJ, ed. *Techniques in Wrist and Hand Arthroscopy*. Philadelphia: Elsevier; 2017:250-261.
- Slutsky DJ. Trapeziometacarpal and scaphotrapezial arthroscopy portals. In: Slutsky DJ, Nagle D, eds. *Techniques in Wrist and Hand Arthroscopy*. Philadelphia: Elsevier; 2007: 19-25.
- Slutsky DJ. Wrist arthroscopy. In: Wolfe SW, Hotchkiss RN, Pederson WC, et al. eds. *Green's Operative Hand Surgery*. 6th ed..Philadelphia: Elsevier; 2011:709-741.
- Tham S, Dagge B. Arthroscopic resection of distal scaphoid and tendon interposition for isolated scaphotrapeziotrapezoid arthritis. In: Slutsky DJ, ed. *Principles and practice of wrist surgery*. Philadelphia: Saunders Elsevier; 2010: 457-462.
- Corbin C, Warwick D. Midcarpal instability after excision arthroplasty for scapho-trapezial-trapezoid (STT) arthritis. *J Hand Surg.* 2009;34E:537-538.
- Deans V, Naqui Z, Muir L. Scaphotrapeziotrapezoidal joint osteoarthritis: a systematic review of surgical treatment. *J Hand Surg Asian Pac Vol.* 2017;22:1-9.
- Garcia-Elias M, Lluch A. Partial excision of scaphoid: is it ever indicated. *Hand Clin.* 2001;17:687-695.
- Garcia-Elias M, Warwick D., Re: Corbin C, Warwick D. Midcarpal instability after excision arthroplasty for scaphotrapezial-trapezoid (STT) arthritis. *J Hand Surg.* 2010;35:82.

20. Tay SC, Moran SL, Shin AY, et al. The clinical implications of scapho-trapezium-trapezoidal arthritis with associated carpal instability. *J Hand Surg Am.* 2007;32:47-54.
21. Cooney WP, Bussey R. Difficult wrist fractures. *Clin Orthop Rel Res.* 1987;213:136-147.
22. Padua R, Padua L, Ceccarelli E, et al. Italian version of the Disability of the Arm, Shoulder and Hand (DASH) questionnaire. Cross-cultural adaptation and validation. *J Hand Surg Br.* 2003;28:179-186.
23. Fairplay T, Atzei A, Corradi M, et al. Cross-cultural adaptation and validation of the Italian version of the patient-rated wrist/hand evaluation questionnaire. *J Hand Surg Eur Vol.* 2012;37:863-870.
24. Badur N, Luchetti R, Atzei A. Arthroscopic wrist anatomy and setup. In: Geissler WB, ed. *Wrist and Elbow Arthroscopy: A Practical Surgical Guide to Techniques.* 2nd ed..New York: Springer Verlag; 2015:1-28.
25. Luchetti R, Atzei A. *Artroscopia di polso.* Parma, Italy: Mattioli 1885; 2001.
26. Atzei A, Luchetti R, Sgarbossa A, et al. Set-up, portals and normal exploration in wrist arthroscopy. *Chir Main.* 2006;25: S131-S144.
27. del Piñal F, Garcia-Bernal FJ, Pisani D, et al. Dry arthroscopy of the wrist: surgical technique. *J Hand Surg.* 2007;32:119-123.
28. Geissler WB, Haley TH. Arthroscopy management of scapholunate instability. *Atlas Hand Clin.* 2001;6:253-274.
29. Messina J, Dreant N, Van Overstraeten L, et al. Evolution of arthroscopic classification in scapholunate complex lesions. *J Hand Surg Br.* 2012;37:S85-S86.
30. Berkhout MJ-L, Bachour Y, Wessing D, et al. Distal pole resection of the scaphoid for the treatment of scaphotrapezio-trapezoid osteoarthritis. *Hand.* 2019;14:230-235. doi:10.1177/1558944717735939.
31. Fontes D. Traitement de l'arthropathie scapho-trapézo-trapézoïdienne par résection arthroscopique du pied du scaphoïde-étude prospective à propos de 8 cas. Personal communication at GEM, Paris, 1999.